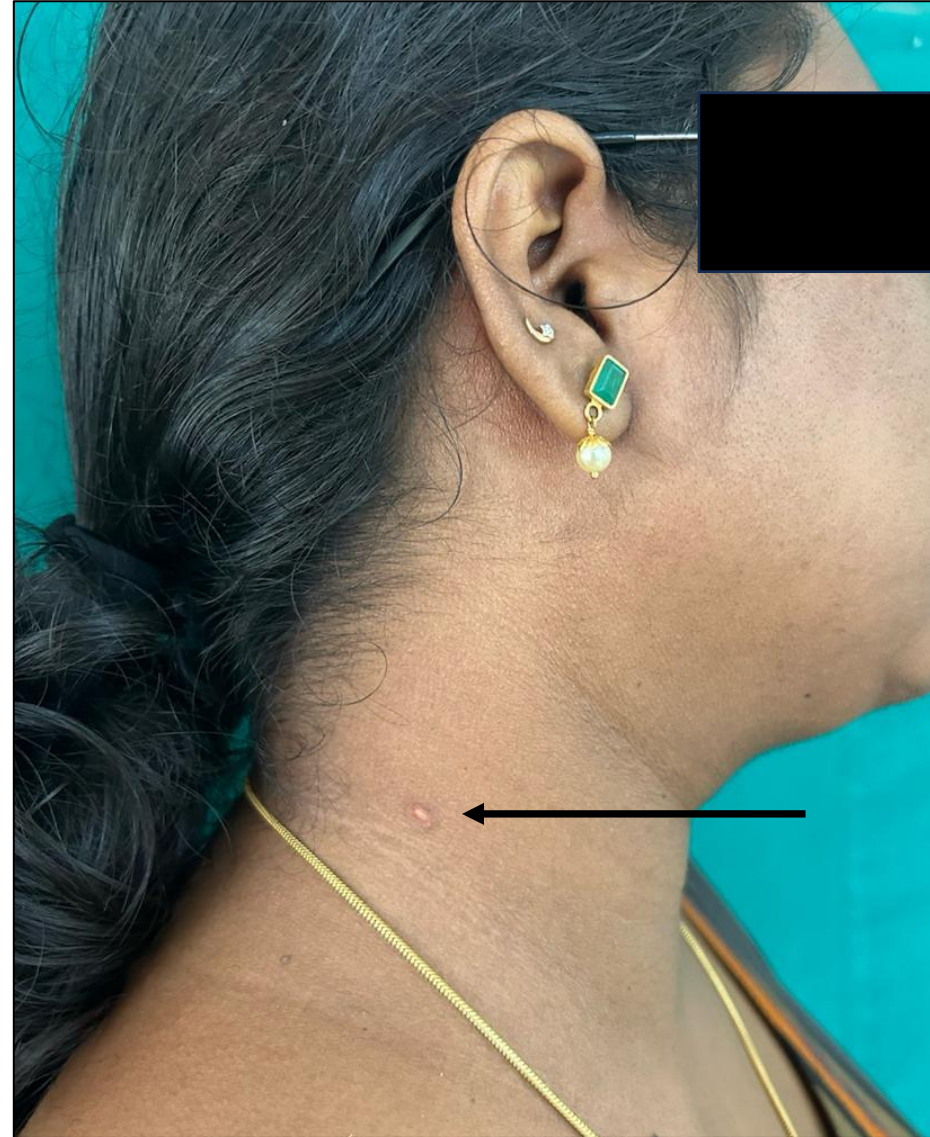

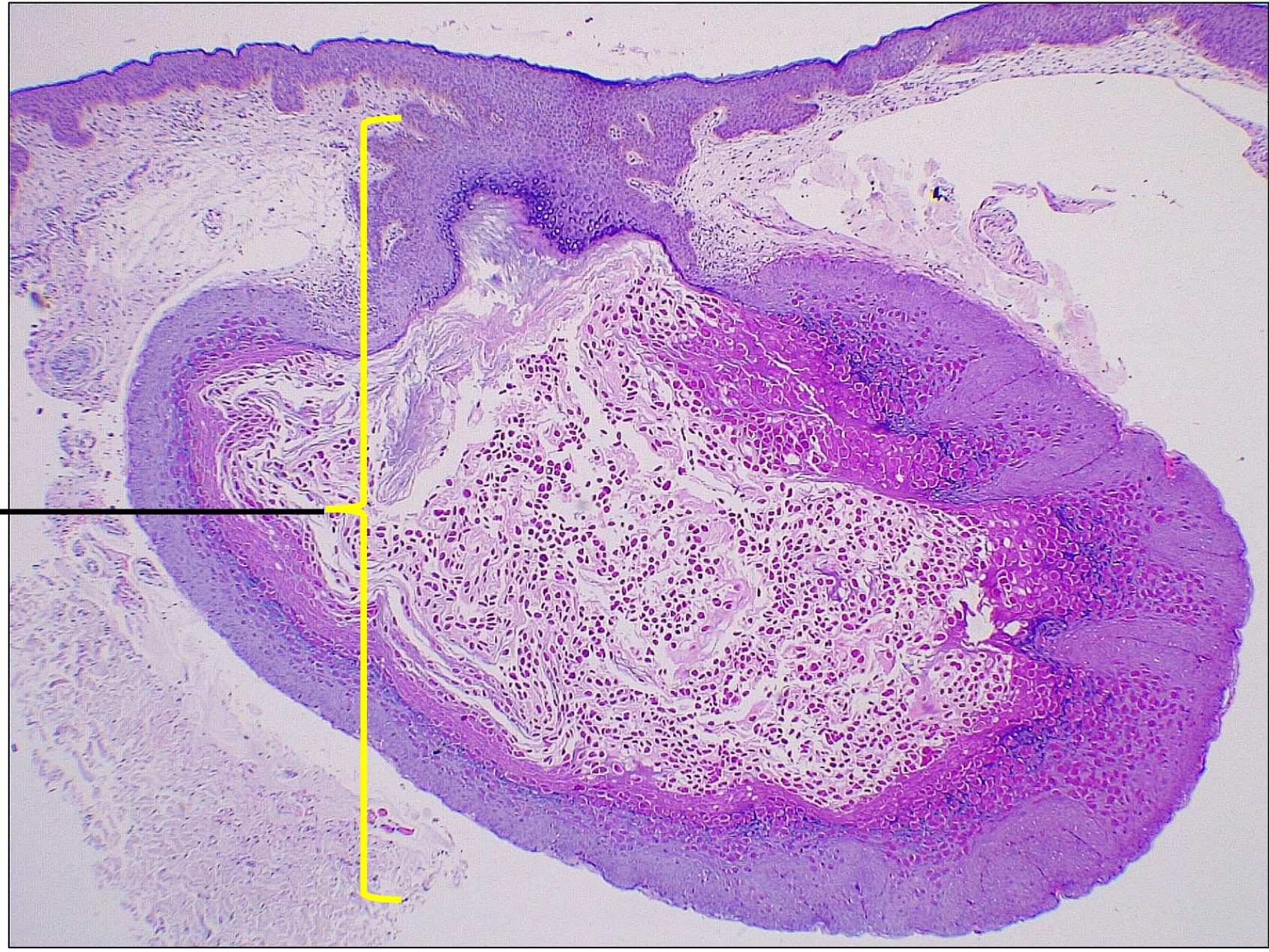

DERMA PEARLS: DERMPATH PEARL - 12

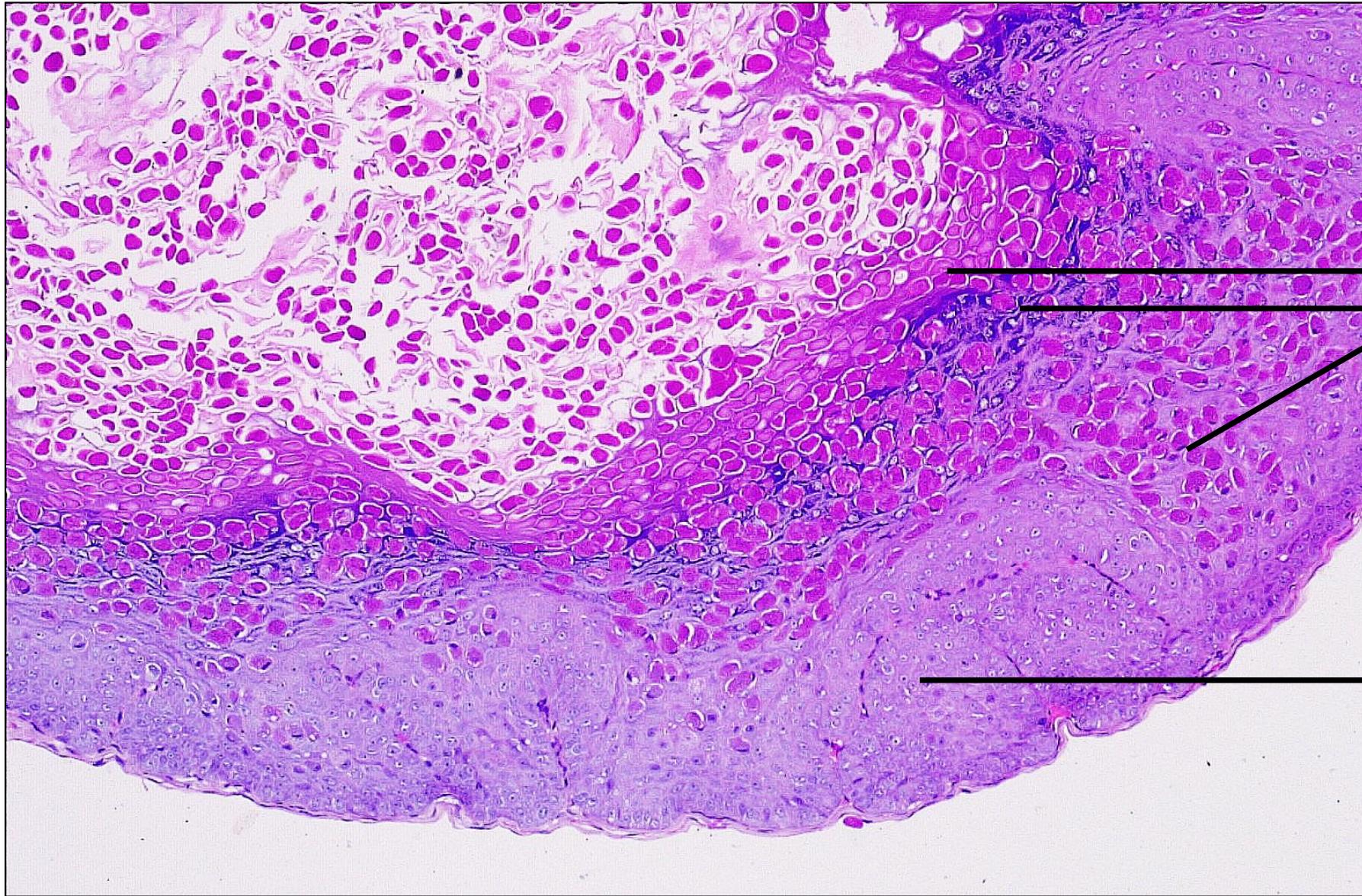
22/F;
C/O: Asymptomatic lesion on
the neck for 3 months;
O/E: Single, well-defined yellow
to skin-colored papule
measuring 0.5 x 0.5 cm over the
right side of the neck.



Courtesy: Dr P Guru Prasad, Prof & HOD, King George Hospital, Visakhapatnam.

There is epidermal
invagination

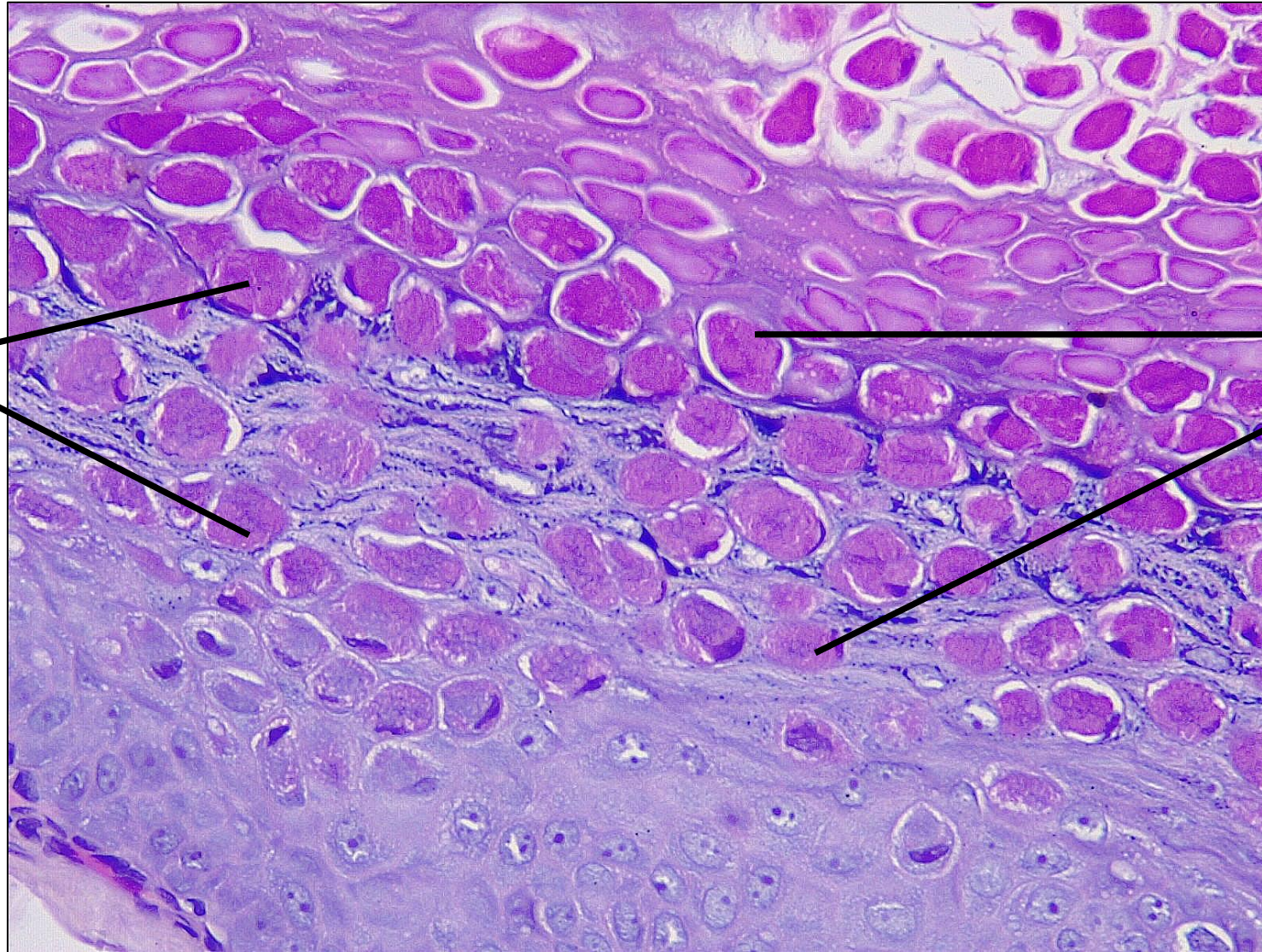




The corneal layer, granular layer and the spinous layer show inclusion bodies

There is mild epidermal acanthosis

Diagnosis : Molluscum contagiosum



Molluscum bodies
or
Henderson-
Paterson bodies

Solitary,
Intracytoplasmic,
Eosinophilic
Inclusion bodies